Transplant International ISSN 0934-0874

ORIGINAL ARTICLE

Angioplasty treatment of hepatic vein stenosis in pediatric liver transplants: long-term results

Yu Fan Cheng,[1] Chao Long Chen,[2] Tung L. Huang,[1] Tai Yi Chen,[1] Yaw Sen Chen,[2] Chih Chi Wang,[2] Leo Leung-chit Tsang,[1] Po Lin Sun,[1] King Wah Chiu,[3] Hock-Liew Eng[4] and Bruno Jawan[5]

1 Department of Diagnostic Radiology and Liver Transplant program, Chang Gung memorial Hospital, Kaohsiung Medical Center, Chang Gung University, Kaohsiung, Taiwan
2 Department of Surgery, Chang Gung memorial Hospital, Kaohsiung Medical Center, Chang Gung University, Kaohsiung, Taiwan
3 Department of Hepatogastroentrology, Chang Gung memorial Hospital, Kaohsiung Medical Center, Chang Gung University, Kaohsiung, Taiwan
4 Department of Pathology, Chang Gung memorial Hospital, Kaohsiung Medical Center, Chang Gung University, Kaohsiung, Taiwan
5 Department of Anesthesiology, Chang Gung memorial Hospital, Kaohsiung Medical Center, Chang Gung University, Kaohsiung, Taiwan

Keywords
angioplasty, hepatic vein, liver transplant.

Correspondence
Yu Fan Cheng MD, Department of Diagnostic Radiology and Liver Transplant program, Chang Gung Memorial Hospital, Kaohsiung Medical Center, 123, Tai Pei Road, Kaohsiung 83305, Taiwan. Tel.: 883 7 7317123; fax: 883 7 7331415; e-mail: cheng.yufan@msa.hinet.net

Received: 20 April 2004
Revised: 10 November 2004
Accepted: 1 December 2004

doi:10.1111/j.1432-2277.2005.00088.x

Summary

We reviewed long-term results of percutaneous venoplasty in children with hepatic vein stenosis after partial liver transplants, of which excellent early results were shown. Percutaneous transjugular hepatic venoplasty using balloon dilatation or stent implantation was performed in six cases with hepatic vein stenosis identified on routine post-transplant Doppler sonography and confirmed by transjugular hepatic venography from 1994 to 2003. Repeated procedure was carried out if necessary. Six of 105 patients with partial liver graft developed hepatic stenosis characterized by low hepatic venous velocity with monophasic waveform with significant pressure gradient (>5 mmHg). The incidence was 4.46% for all 112 pediatric liver transplants. Successful balloon venoplasty was achieved in four cases. Self-expanding stent was used in two cases with absent waisting or angulated balloon catheter during dilatation and persisted pressure gradient (>5 mmHg). Repeated procedure was required in two initially successful cases with additional stent used in one case. Three cases had transient hyperdynamic hepatic venous flow with markedly increased central venous pressure after stent implantation. Nonprocedural-related mortality rate was 16.7%. Patent hepatic vein was maintained in five patients after a mean follow-up of 3.67 years (0.75–9.5). Higher incidence of hepatic vein stenosis was noted in pediatric partial liver transplant. However, encouraging long-term results showed that hepatic venoplasty or stent implantation could be a preferable alterative to surgical revision or retransplantation, which has been the procedure of choice in our hospital.

Introduction

Liver transplantation is the major therapeutic option for end-stage liver disease as recent improvement in surgical techniques, immunosuppressants and organ utilization contribute to better post-transplant outcome [1, 2]. However, significant graft failure as a result of vascular complications is still noted, especially in partial liver transplant with living donor graft where the use of short vascular pedicle complicates the surgical procedures [3]. Moreover, the younger age and less body weight in children compared with adults also offer them higher risk of surgical-related complications [4]. The few postoperative hepatic venous insults that occurred in our pediatric series were managed according to the severity of clinical signs and symptoms of the patients. Balloon angioplasty and vascular stent placement are therapeutic options that achieved satisfactory initial results [5]. Nonetheless, this

unprecedented modified management also implies unpredictable long-term results as these pediatric patients increase in size and weight. We reported the prevalence, Doppler ultrasound findings, angioplasty, application of metallic stent, and outcome for hepatic vein stenosis in pediatric recipients after liver transplant.

Methods and materials

A total of 112 pediatric liver transplants consisting of 56 boys and 56 girls, with age of 2.08 ± 3.55 years (mean ± SD; range: 0.58–15) were performed at Chang Gung Memorial Hospital, Taiwan, from March 1994 to May 2003. Of all the patients, nine had cadaveric liver transplants including split liver graft ($n = 7$), reduced size liver graft ($n = 5$) and whole liver graft ($n = 7$), while 93 had living donor grafts. The underlying diseases were biliary atresia ($n = 85$), Wilson's disease ($n = 4$), glycogen storage disease ($n = 6$), hemangiopericytoma ($n = 1$), neonatal hepatitis ($n = 5$), Allaglle syndrome ($n = 1$), hepatitis B cirrhosis ($n = 4$) and fulminant hepatitis ($n = 1$). All cases with biliary atresia had undergone at least one Kasai operation in early infancy. The body weight was 11 ± 8.53 kg (mean ± SD; range: 5.6–50). The graft weight recipient ratio was 2.8 ± 0.89 (mean ± SD; range: 1.27–4.66).

In the recipient, the diseased liver was removed leaving the inferior vena cava intact with the right hepatic vein and the trunk of middle hepatic vein and left hepatic vein clamped separately. The inferior vena cava was then cross-clamped above and below the hepatic veins. Then clamps on the hepatic veins were released. A triple hepatic venoplasty was performed to create an adequate outflow orifice. In some older pediatric recipients, a double hepatic venoplasty consisting of the middle hepatic vein and left hepatic vein was used in the early learning period with the right hepatic vein sutured closed without cross-clamping the inferior vena cava. On the graft side, the hepatic vein of the graft was carefully inspected after procurement. If two or more orifices were found, a venoplasty was performed to fashion a single wide outflow orifice for a single hepatic vein anastomosis. Whenever possible, the correct orientation of the graft and recipient vessels was maintained.

Hepatic vein stenosis was first suspected when patient developed persistent ascites or edema and diagnosed by routine postoperative Doppler ultrasound. CT scan or multislice CT angiography and angiography were considered if further complications were suspected. All angiographic procedures were performed with patient under general anesthesia. The right internal jugular vein was used as vascular access for hepatic vein venography. If a stenosis was identified, hepatic vein venoplasty was carried out immediately. Pre- and poststenotic hepatic venous pressures as well as pull-through pressures were measured. A stiff guide wire with diameter 0.035-inch was used to pass through the stenotic segment. The stenotic area was dilated with balloon angioplasty after the administration of a heparin bolus directly into the stenotic hepatic vein. An appropriate sized metallic stent was employed in cases with absence of waisting and persistent pressure gradient during balloon dilatation or recurrent stenosis with persistent pressure gradient (>5 mmHg) after dilatation. Patient underwent systemic anticoagulation with heparin sodium to maintain a partial thromboplastin time of 1.5 times greater than normal levels, immediately after the procedure.

Results

Five cases transplanted at our hospital and one at another hospital were diagnosed of hepatic vein stenosis (Table 1). The incidence of hepatic vein stenosis of our group was 4.46% (five of 112). No hepatic stenosis was noted in those with whole cadaveric grafts while 4.76% (five of 105) with partial liver grafts. Among the partial liver graft recipients, the incidence was 28.57% (two of seven) for split grafts and 3.22% (three of 93) for living donor liver grafts. The onset of hepatic vein stenosis was 1–5 months (mean: 2.66 months) after transplant.

Balloon dilatation and metallic stent insertion

The presence of a significant pressure gradient of 11.5 ± 4.5 mmHg (range: 8.7–17.5 mmHg) was confirmed in six suspected cases based on clinical and Doppler ultrasound (Table 2; Figs 1–3). Hepatic venography showed narrowed anastomotic site, stasis of contrast

Table 1. Summary of characteristics of the pediatric liver transplant.

	Number of cases	Mean ± SD	Range	*P*-value
Age (years)				NP
Total cases	112	2.08 ± 3.55	0.5–15	
Cases without HV stenosis	107	1.4 ± 3.5	0.5–15	
Cases with HV stenosis	5	2.7 ± 2.03	1.4–6	
Body weight (kg)				NP
Total cases	112	11 ± 8.53	5.6–50	
Cases without HV stenosis	107	8.1 ± 7.47	5.6–50	
Cases with HV stenosis	5	11.5 ± 4.67	8–21	
GRWR				NP
Total cases	112	2.8 ± 0.89	1.27–4.66	
Cases without HV stenosis	107	3 ± 0.93	1.27–4.66	
Cases with HV stenosis	5	2.3 ± 0.85	1.54–3.6	

GRWR, graft recipient weight ratio; NP, normal.

Table 2. Summary of characteristics of patients with hepatic vein stenosis after liver transplant.

Case no.	Type of transplant	Age (years)	Onset or recurrent of HV stenosis (months)	Type and no. venoplasty	Outcome
1	Reduced size LT	6	5	Balloon	F/U 9.5 years
2	LDLT	6	1	Stent	F/U 4.5 years
3	Split LT	2	5	Stent	Died 1 month after venoplasty
4	Split LT	3	1	Balloon	Recurrent
			1	Balloon	Recurrent
			1	Stent	F/U 2 years
5	LDLT	2	2	Balloon	Recurrent
			0.75	Balloon	F/U 1.6 years
6	LDLT	2.4	2	Balloon	F/U 9 month

LT, liver transplant; HV, hepatic vein; F/U, follow-up.

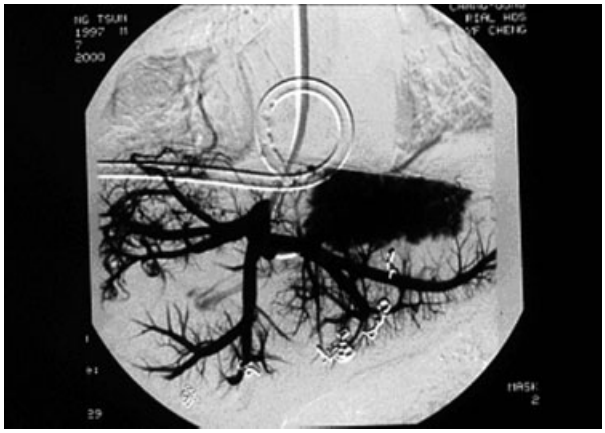

Figure 1 Hepatic vein angiography shows stenosis of the hepatic vein with contrast medium stasis in the liver parenchyma.

Figure 2 No waisting was found during balloon dilatation.

medium in the liver parenchyma with delayed washout. Venoplasty with 8 and 10 mm dilatation balloon (Boston Scientific, Watertown, MA, USA) was performed in all six

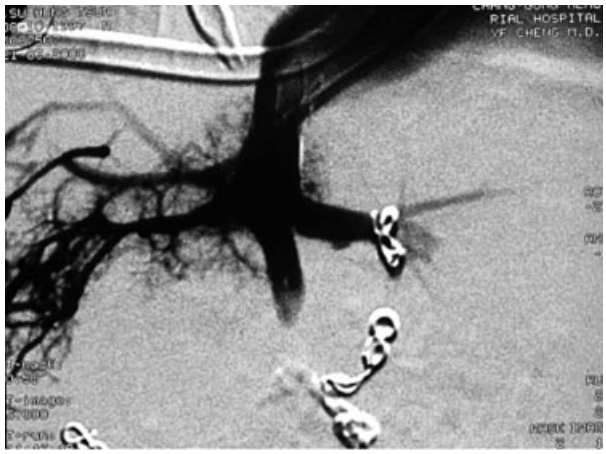

Figure 3 Patency of the hepatic vein after metallic stent insection.

cases, of whom four showed satisfactory outcome of an immediate pressure gradient reduction of 1.71 ± 1.1 mmHg (range: 0–4 mmHg) with patent hepatic vein and rapid washout of contrast medium. The other two cases had absent waisting or angulated balloon catheter during dilatation with persistent pressure gradient (>5 mmHg) even after dilatation. Self-expanding Symphony stent (Boston scientific) of 10 mm in diameter and 22 mm in length was employed for the two cases. Repeated angioplasty was required for recurrent hepatic vein stenosis, presented with massive ascites in two cases. One patient experienced third episode of stenosis 1 month after the initial treatment and required self-expanding symphony stent insertion.

Findings of the Doppler ultrasound

Doppler ultrasound studies revealed an increase in hepatic venous blood flow velocity from 8–18 cm/s (mean: 13.66 cm/s) before dilatation to 27–162 cm/s (mean:

77.83 cm/s) after balloon dilatation or stent insertion (Table 3). The waveform was also resumed from monophasic before dilatation to biphasic or triphasic after treatment. Moreover, an accompanied increase in portal venous flow from 12–15 cm/s (mean: 13 cm/s) to 30–49 cm/s (mean: 42.5 cm/s) was noted after the relief of high hepatic venous outflow resistance upon successful manipulation.

Long-term follow-up

The success rate of balloon dilatation was only 50% (3/6) but was elevated to 100% with the additional metallic stent insertion (Table 3). Marked increase in hepatic venous velocity (>100 cm/s) and central venous pressure were observed in the three patients with metallic stent insertion. Symptoms of pulmonary edema with tachycardia and tachypnea arose but were well controlled by diuretics (Table 3). There were no procedure-related complications and one patient died of other medical complications. Improved ascites, edema and serum levels of liver enzymes were noted immediately after angioplasty. Long-term follow-up revealed patent hepatic vein with functioning graft in five patients (range: 0.75–9.5 years; mean: 3.67 years). The actuarial survival rate of liver transplantation in our series is 91% and the living related liver transplant recipients with functioning grafts was 97.6%.

Discussion

Advanced surgical techniques such as the utilization of reduced size, split and living donor liver grafts, validate liver transplantation for children with end-stage liver disease in Asia where cadaveric grafts are scarce [6, 7]. However, shortened vascular pedicles resulting from a split graft, imply more post-transplant complications because of the size discrepancy of the vessels and the increased surgical difficulty in putting the implants in the correct position without compromising the patency of the anastomoses [4]. We experienced a few cases of hepatic vein stenosis in partial graft liver transplant although the occurrence has been reported to be rare compared with other vascular complications [8]. Low velocity and monophasic Doppler waveform is suggestive of the diagnosis which can be demonstrated by a significant pressure gradient across the anastomosis on angiography [9, 10]. Balloon dilatation through a transjugular, transfemoral, or direct transhepatic approach could achieve satisfactory results.

Controversies still exist about the causes of post-transplant hepatic vein stenosis, which may affect the surgical options. Piggyback technique was applied to all full size

Table 3. Findings of the Doppler ultrasound and outcome of the patients with hepatic vein stenosis.

Case no.	Type and no. venoplasty	Velocity of HV before venoplasty (cm/s)	Velocity of HV after venoplasty (cm/s)	Velocity of HV (cm/s) in the last F/U	CVP before HV dilatation (cmH_2O)	CVP after HV dilatation (cmH_2O)	Waveform of HV before Venoplasty	Waveform of HV after Venoplasty	Waveform of HV in The last F/U	Outcome
1	Balloon	8	27	20	10	11	Monophasic	Biphasic	Biphasic	F/U 9.5 years
2	Stent	8	103	45	11	24	Monophasic	Biphasic	Biphasic	F/U 4.5 years
3	Stent	10	162	75	11	23	Monophasic	Biphasic	Biphasic	Expired 1 month after venoplasty
4	Balloon	24	36		11	9	Monophasic	Biphasic to monophasic		Recurrent (1 month)
	Balloon	23	50		12	12	Monophasic	Biphasic to monophasic		Recurrent (1 month)
	Stent	28	110	83	10	24	Monophasic	Biphasic	Biphasic	F/U 2 years
5	Balloon	14	83		11	12	Monophasic	Triphasic to monophasic		Recurrent (1 month)
	Balloon	43	63	40	11	12	Monophasic	Triphasic	Biphasic	F/U 1.6 years
6	Balloon	18	56	41	5	7	Monophasic	Triphasic	Triphasic	F/U 9 months

HV, hepatic vein; F/U, follow-up.

and partial liver transplantation in our series to avoid veno-venous bypass for the maintenance of normal venous return. In the two cases that required repeated balloon dilatation, sustained waisting over the balloon catheter during dilatation that could be relieved after balloon inflation was observed. We concluded that it is the structural narrowing of the true orifice of the hepatic vein because of the anastomosis of the small vein graft with the common orifice of the recipient's left and middle hepatic vein. We had overcome the problem successfully in our subsequent cases, especially in low body weight children, by creating a bigger common trunk with the recipient's three hepatic veins to ensure a large longitudinal anastomotic orifice for the recipient inferior vena cava to maintain adequate venous drainage even if the graft rotated to the right.

The other two cases that required the self-expanding stent had unchanged monophasic Doppler waveform after dilatation. They also demonstrated outflow twisting or kinking with absent waisting and angulation of balloon catheter. Constant pressure gradient during initial dilatation was noted without a demonstrable fixed stricture point. The cause could be weakened vascular wall, which is different from structural surgical anastomotic stricture that is amendable by traditional balloon angioplastic dilatation alone [9]. We applied the expanding metallic stent to straighten and strengthen the vascular wall around the anastomosis. The reduction of venous pressure gradient, across the stenosis to almost zero had proved that the size of the stent lumen was acceptable and the use of metallic prosthesis was practical in maintaining adequate venous outflow. Hence, we concluded that metallic prosthesis implantation is a feasible therapeutic option in selected cases that experience hepatic venous outflow twisting or kinking because of ill-positioning of the venous anastomosis to avoid surgical revision or re-transplantation.

The selection of stent depends on the size of the lumen, the network and the position of the stents. Size is of utmost importance in pediatric cases as the lumen must maintain adequate hepatic outflow throughout the growth of the child. A larger stent with a bigger profile of the accompanied accessory apparatus could be harmful on applying to small children transjugularly or transfemorally. Large network stent was used to prevent interference with blood flow from other branches of the hepatic veins inside the liver graft. Appropriate position of the stent is critical in preventing any floating portion of the stent from adhering to the inferior vena cava after endothelialization, that would interfere with further transplantation if necessary. Thus, the middle portion of the metallic stent was placed at the stenotic site while the distal portion just over the narrowing point. Therefore, a 1.0 mm self-expanding metallic stent with large network was thought to be the best choice. In the long-term follow-up, sufficient hepatic outflow was maintained in all the surviving cases in which body weight and height increased. In case 2, body weight increased from 21 to 42 kg, 4.5 years after the intervention.

Successful venoplasty reversed the initially decreased mean flow velocity and flat wave pattern of the stenotic hepatic vein to normal patterns [11]. However, dramatic increases in hepatic venous flow of velocity above 100 cm/s and central venous pressure from 10–11 to 23–24 cmH_2O were noted in three cases, right after successful metallic stent insertion. This phenomenon can be attributed to a sudden relief of the posthepatic portal hypertension by an opening stent that triggers a hyperdynamic blood flow from the congestive portal circulation [12]. Although this could be well managed by diuretics, it would be a risk factor for patient with right heart disease.

In our series, the incidence of hepatic vein stenosis in pediatric liver transplant is 5.71% focussing on partial liver graft. They were amenable by venoplasty using balloon dilatation or stent implantation with a successful rate of 100%. The absence of waisting during dilatation, unchanged pressure gradient and flattened Doppler waveform after dilatation necessitate the use of metallic stent. Sustained patency with adequate hepatic outflow is well-maintained during rapid growth in children with long-term survival.

Acknowledgements

This work was supported by project grant NHRI-GT-EX92-9228SP from the National Health Research Institutes and NSC 90-2314-B-182A-092 and NSC 91-2314-B-182A-168 from the National Science Council, Taiwan.

References

1. Tanaka K, Uemoto S, Tokunaga Y, *et al.* Surgical techniques and innovations in living related liver transplantation. *Ann Surg* 1993; **217**: 82.
2. Fan ST, Lo CM, Liu CL. Technical refinement in adult-to-adult living donor liver transplantation using right lobe graft. *Ann Surg* 2000; **231**: 126.
3. Settmacher U, Nussler NC, Glanemann M, *et al.* Venous complications after orthotopic liver transplantation. *Clin Transplant* 2000; **14**: 235.
4. Buell JF, Funaki B, Cronin DC, *et al.* Long-term venous complications after full-size and segmental pediatric liver transplantation. *Ann Surg* 2002; **236**: 658.
5. Raby N, Karani J, Thomas S, O'Grady J, Williams R. Stenoses of vascular anastomoses after hepatic transplantation: treatment with balloon angioplasty. *AJR Am J Roentgenol* 1991; **157**: 167.

6. Otte JB, de Ville de Goyet J, Reding R, *et al.* Pediatric liver transplantation: from the full-size liver graft to reduced, split, and living related liver transplantation. *Pediatr Surg Int* 1998; **13**: 308.
7. Otte JB. History of pediatric liver transplantation. Where are we coming from? Where do we stand? *Pediatr Transplant* 2002; **6**: 378.
8. Tzakis AG, Gordon RD, Makowka L, *et al.* Clinical considerations in orthotopic liver transplantation. *Radiol Clin North Am* 1987; **25**: 289.
9. Egawa H, Tanaka K, Uemoto S, *et al.* Relief of hepatic vein stenosis by balloon angioplasty after living-related donor liver transplantation. *Clin Transplant* 1993; **7**: 306.
10. Cheng YF, Huang TL, Chen CL, *et al.* Intraoperative Doppler ultrasound in liver transplantation. *Clin Transplant* 1998; **12**: 292.
11. Huang TL, Chen TY, Chen CL, *et al.* Hepatic outflow insults in living-related liver transplantation: by Doppler sonography. *Transplant Proc* 2001; **33**: 3464.
12. Jawan B, Cheung HK, Chen CC, *et al.* Repeated hypotensive episodes due to hepatic outflow obstruction during liver transplantation in adult patients. *J Clin Anesth* 2000; **12**: 231.